Supplementary Table 1. Studies included in the scoping review and their characteristics

Author, year	Country	Sample	Diagnostic image method	Mean EARR (mm/mm³/%)	Outcome (prevalence)	Orthodontic technique
Li Y, 2020	China	70 patients (373 teeth)	3D	fixed appliances: (1.12±1.34/-/-) centrals: (1.23±1.31/-/-) laterals: (1.31±1.33/-/-)	fixed appliances: 0 (18.16%) 1 (61.79%) 2 (19.24%) 3 (0.81%)	Fixed appliances
				clear aligners: (0.13±0.47/-/-) centrals: (0.26±0.42/-/-) laterals: (0.23±0.37/-/-)	clear aligners: 0 (43.7%) 1 (56.30%) 2 (0%) 3 (0%)	Removable appliances
Wichelhaus A, 2020	Germany	36 patients (18 controls/18 test)	2D	-	rRCR 94,4% in control group no EARR: 5.6% light EARR: 48.6% moderate EARR: 33.3% severe: 12.5%	Fixed appliances
				-	rRCR 89% in TSA group no EARR: 11.1% light EARR: 55.6% moderate EARR: 30.6% severe: 2.8%	
Pamukçu H, 2019	Türkiye	60 patients (120 teeth)	2D	-	Labial and lingual group no EARR: 53.6% (720 teeth) slight EARR: 23.3% (168 teeth) moderate EARR: 14.7% (106 teeth) severe EARR: 8.3% (60 teeth) Labial group general: no EARR: 56.1% (202 teeth) mild: 19.7% (71 teeth) moderate: 14.7% (53 teeth) severe: 9.4% (34 teeth)	Fixed appliances
				-	Lingual group general: no EARR: 51.1% (184 teeth) mild: 26.9% (97 teeth) moderate: 14.7% (53 teeth) severe: 7.2% (26 teeth)	
Gay G, 2017	Italy	71 patients	2D	-	no EARR: 58.12% (630 teeth) mild: 25.94% (281 teeth) moderate: 12.18% (13 teeth) severe: 3.69% (40 teeth)	Removable appliances
Ciurla A, 2021	Poland	101 patients (61 controls/40 cases)	2D	-	control group without EARR (with 0.90≤ rRCR ≤1.00) no EARR: 1.97% (12 teeth) mild EARR: 98.03% (598 teeth) moderate EARR: 0% severe EARR: 0% cases group with EARR (rRCR <0.90) mild EARR: 75.25% (301 teeth) moderate EARR: 17.25% (69 teeth) severe EARR: 5.75% (23 teeth)	Fixed appliances
Neves BM, 2021	Brazil	326 patients (1304 teeth)	2D	-	EARR: 53.68% (700 teeth between level 2-4) no EARR 46.32% (604 teeth between level 0-1)	Fixed appliances
Janson G, 2021	Brazil	54 patients (27 elastic / 27 Headgear group)	2D	-	Maxillary and mandibular incisors 0: 0 (0%) elastic/2 (0.92%) Headgear 1: 184 (85.18%) elastic/190 (87.96%) Headgear 2: 32 (14.81%) elastic / 17 (7.87%) Headgear 3: 0 (0%) elastic/5 (2.31%) Headgear 4: 0 (0%) elastic/2 (0.92%) Headgear	Fixed appliances
Liu W, 2021	China	40 patients	3D	11: (-/14.62±6.86/7.95±3.58) 21: (-/12.62±6.40/6.67±2.92) 12: (-/12.66±6.78/8.42±4.64) 22: (-/11.82±6.50/7.65±4.22)	Maxillary and mandibular incisors: Mild (<10%): 227 (7.94%) Moderate (10-20%): 91 (28.44%) Severe (>20%): 2 (0.63%)	Removable appliances
Linhartova P, 2021	Czech Republic	106 patients (32 EARR/74 controls)	2D	Control no EARR: (0.51±0.50/-/-) EARR (2.31±0.47/-/-)	32 case (>2 mm) 74 control (<2 mm)	Fixed appliances
Da-Costa TMPS, 2018	Brazil	10 patients	2D	11: (1.39/-/7,47)* 21: (1,58/-/8,27)*	100% of EARR one patient presented mild degree (0.44 mm) eight patients presented moderate degree (1.583±0.337mm)one patient presented severe degree (2.3 mm)	Fixed appliances
Jyotirmay, 2021	India	110 patients (55 fixed appliances/55 clear aligners)	3D	fixed appliances general: (1.51±1.34/-/-) Central: (2.03±1.31/-/-) Lateral: (1.40±1.33/-/-)	General (for all the teeth) 0: 112 (19.45%) fixed/260 (45.13%) clear aligners 1: 359 (62.32%) fixed/316 (54.86%) clear aligners 2: 102 (17.70%) fixed/0 (0%) clear aligners 3: 3 (0.005%) fixed/0 (0%) clear aligners	Fixed appliances
				clear aligners general: (1.12±1.34/-/-) central: (1.23 ± 1.3/-/-) lateral: (1.31 ± 1.33/-/-)		Removable appliances
Sepanian VF, 2017	Denmark	74 patients 1 phase: 336 incisors 2 phase: 201 incisors	2D	-	1 phase group central maxillary incisor : aprox 45% of EARR lateral maxillary incisor: aprox 65% of EARR	Fixed appliances
					2 phase group central maxillary incisor: aprox 35% of EARR lateral maxillary incisor: aprox 62%	
Handem RH, 2016	Brazil	52 patients	2D	group 2 conventional: 11: (0.59/-/-) 21: (0.66/-/-) 12: (0.70/-/-) 22: (0.74/-/-)	no EARR: 207 (49.7%) mild: 157 (37.7%) moderate: 44 (10.5%) accentuated: 8 (1.9%)	Fixed appliances
				group 1 self-ligating: 11: (0.72/-/-) 21: (0.88/-/-) 12: (0.72/-/-) 22: (0.80/-/-)	Group 2: 0: 114 (52.7%) 1: 74 (34.2%) 2:24 (11.1%) 3: 4 (1.85%) 4:0 (0%) Group 1: 0: 93 (46.5%) 1: 83 (41.5%) 2:20 (10%) 3: 4 (2%) 4:0 (0%)	
Iglesias-Linares A, 2012	Spain	54 patients	2D	NO EARR: control: (1.06±0.503/-/-) affected: (3.12±0.709/-/-)	<2 mm: 29 patients >2 mm: 25 patients	Fixed appliances
Krieger E, 2013	Germany	100 patients	2D	-	no EARR (rRCR ≥100%) : 54% (864) mild (90≤ rRCR <100): 11.94% (191) moderate (80≤ rRCR <90): 27.75% (191) severe (rRCR <80):6.31% (101)	Removable appliances
Iglesias-Linares A, 2014	Spain	87 patients	2D	-	>2 mm: 37 patients <2 mm: 50 patients	Fixed appliances
Picanço GV, 2011	Brazil	99 patients	2D	-	0-1 grade n: 50 3-4 grade n: 49	Fixed appliances
Jacobs C, 2014	Germany	213 patients (139: SL and 74: non-SL) SL* : self-ligating	2D	Non-SL: (-/-/4.5±6.6) SL: (-/-/3.0±5.6)	severe EARR: Non-SL 0.5% vs. SL: 0.3% (upper incisor with severe EARR: central 1 (0.2%) lateral 1 (0.2%)	Fixed appliances
Qin F, 2019	China	98 patients (49 conventional, 49 Damon)	2D	Conventional: 11: (0.4/-/-) 21: (0.39/-/-) 12: (0.3/-/-) 22: (0.31/-/-)	Conventional: 0: 5 (10%) 1: 12 (25%) 2: 20 (41%) 3: 7 (14%) 4: 5 (10%)	Fixed appliances
				Damon: 11: (0.32/-/-) 21: (0.33/-/-) 12: (0.27/-/-) 22: (0.28/-/-)	Damon: 0: 4 (8%) 1: 20 (41%) 2: 18 (37%) 3: 4 (8%) 4: 3 (6%)	
Iglesias-Linares A, 2017	Spain	372 patients	2D		174 patients (affected) 198 patients (control)	Fixed appliances
Rakhshan V, 2012	Iran	132 patients	2D	General: (1.377±1.214/-/8.165±8.021) central: (-/-/6.39±6.80) lateral (-/-/7.15±7.15)	The prevalence of EARR, and clinical EARR (≥1.2 mm) were 91.8% and 44.78% respectively	Fixed appliances
Ramanathan C, 2009	Czech Republic	49 patients group 1: 15 group 2: 17 group 3: 17	2D	group 1: central: (0.26±0.24/-/-) group 2 central: (0.46±0.32/-/-) group 3: central (0.25±0.37/-/-)	Prevalence of root resorption of 0.5-0.9mm group 1: 13% group 2: 53% group 3: 18%	Fixed appliances
Al-Qawasmi RA, 2003	USA	73 patients	2D	-	n=33 (>2 mm): 45.2%	Fixed appliances
Castro IO, 2013	Brazil	30 patients	3D	Central (0.46/-/-) Lateral: (0.49/-/-)	Central: 73% Lateral: 73% 100% patients with EARR 46% of the 1256 roots with ARR.	Fixed appliances
Artun J, 2009	Kuwait The Netherlands USA	267 patients	2D	General mean: (1.10±1.02/-/-) 11: (1.01±1.05/-/-) 21: (0.88±1.17/-/-) 12: (1.24±1.26/-/-) 22: (0.95±1.17/-/-)	>2 mm: 16.5% >3 mm: 5.2% >4 mm: 1.5%	Fixed appliances
Apajalahti S, 2007	Finland	601 patients	2D	(-/-/-)	grade 1: 16.3% (n=98) 38 males (15%) /60 females (17%) grade 2: 8.6% (n=52) 17 males (6.7%) /35 females (10%)	Fixed appliances Removable appliances
Lund H, 2012	Sweden	152 patients	3D	PER MONTH: central (-0.043±0.048 (6month) / -0.084±0.498 (till the end) /-/-) lateral (-0.049±0.058 (6month) / -0.154±0.653 (till the end) /-/-)	Final treatment Central: >0 mm: 266 (87.5%) >1 mm: 126 (41.4%) >2 mm: 44 (14.5%) >3 mm: 21 (6.9%) >4 mm: 8 (2.6%) Lateral: >0 mm: 278 (91.4%) >1 mm: 171 (56.3%) >2 mm: 67 (22%) >3 mm: 25 (8.2%) >4 mm: 8 (2.6%)	Fixed appliances
Maurya RK, 2022	India	80 patients	2D	-	100% grade 2 (in all of the groups)	Fixed appliances
Nigul K, 2026	Estonia	75 patients	2D	11: (1.61±1.27/-/-) 21: (1.48±1.05/-/-) 12: (1.57±1.2/-/-) 22: (1.35±1.02/-/-)	0: 12% (12:11; 11:11; 21:9; 22:9) 1: 64% (12:46; 11:37; 21:46; 22:48) 2: 14.6% (12:11; 11:18; 21:15; 22:11) 3: 2.6% (12:3; 11:2; 21:2; 22:2)	Fixed appliances
Elhaddaoui R, 2016	Morocco	82 patients	2D	-	The prevalence of EARR in our sample was 95%. Score 0: 5% no resorption (16) Score 1: 35.7% were slight resorptions (113) Score 2: 40.3% were moderate (128) Score 3: 19% severe resorptions (61)	Fixed appliances
Marques LS, 2010	Brazil	1049 patients	2D	-	severe EARR: 14.5% (152teeth)	Fixed appliances
Mohandesan H, 2007	Iran	40 patients	2D	central 6 months: (0.77±0.42/-/4.5) 12 months: (1.67±0.64/-/9.77) lateral 6 months: (0.88±0.51/-/5.65) 12 months: (1.79±0.66/-/11.44)	EARR clinically significant: 74% central incisor 82% lateral incisor	Fixed appliances
Artun J, 2005	Kuwait The Netherlands	302 patients	2D	11:(0.72±0.79/-/-) 21: (0.66±0.81/-/-) 12: (0.94±1/-/-) 22: (0.78±0.92/-/-)	5.3% have EARR >2 mm 7.7% have EARR >3 mm 2.4% have EARR >4 mm	Fixed appliances
Motokawa M, 2013	Australia Japan	111 patients (Open bite: 54; non-open biten: 57)	2D	-	no EARR: 17 (15.31%) mild EARR (grade 1-2): 69 (62.16%) severe EARR (grade 3-4): 25 (22.5%)	Fixed appliances
Chen W, 2015	China	70 patients (35 damon / 35 conventional)	2D	Conventional Central: (0.5±0.3/-/4.13) Lateral: (0.3±0.3/-/2.60) Damon Central: (0.3±0.4/-/2.61) Lateral: (0.2±0.3/-/2.00)	Conventional: 0: 0 1: 156 (55.71%) 2: 70 (25%) 3: 48 (17.14%) 4: 6 (2.14%) Damon: 0: 0 1: 188 (67.14%) 2: 67 (23.93%) 3: 22 (7.89%) 4: 3 (1.07%)	Fixed appliances
Dudic A, 2009	Switzerland	22 patients (65 incisors)	2D 3D	-	Panoramic: 0: 13 (20%) 1: 42 (64.6%) 2: 10 (15.4%) 3: 0 (0%) CBCT: 0: 9 (13.9%) 1: 27 (41.5%) 2: 27 (41.5%) 3: 2 (3.1%)	Fixed appliances
Remington DN, 1989	USA	100 patients	2D	-	Central: 2 extracted teeth 0: 3 1: 12 2: 136 3: 43 4: 2 Lateral: 7 extracted teeth, 2 unscored 0: 12 1: 7 2: 119 3: 47 4: 6	Fixed appliances
van Loenen, 2007	Belgium	31 patients	2D	Central: (1.4/-/0.89±0.08) Lateral: (1.9/-/0.85±0.10) Central: T1-T2: 0.9 mm T2-T3: 0. 5mm T1-T3: 1.4 mm Lateral: T1-T2: 0.9 mm T2-T3: 1 mm T1-T3: 1.9 mm	70% Central incisor 76% Lateral incisor (at the start of the torquing phase: central 48%/lateral 53%)	Fixed appliances
Levander E, 1998	Sweden	68 patients Group 1: 33 Group 2: 35	2D	-	Group 1: 0: 4 (5%) 1: 23 (31%) 2: 44 (59%) 3: 4 (5%) Group 2: 4-7 agenesis: 0: 5 (5%) 1: 7 (7%) 2: 52 (53%) 3: 34 (35%) 8-16 agenesis: 0: 0 (0%) 1: 2 (15%) 2: 10 (77%) 3: 1 (8%)	Fixed appliances
Beck BW, 1994	USA	83 patients (Begg vs Tweed)	2D	central: (2.1±1.24/-/-) lateral: (-/-/-)	62% central incisor (grade 2-4)	Fixed appliances
Levander E, 1994	Sweden	40 patients group 1: 32 group 2: 30	2D	group 1 general: (1.5±0.8/-/-)	Group 1: 32 teeth 0 mm: 0 (0%) 0.5 mm: 6 (18.75%) 1 mm: 3 (9.4%) 1.5 mm: 10 (31.25%) 2 mm: 6 (18.75%) 2.5 mm: 5 (15.63%) 3 mm: 2 (6.25%)	Fixed appliances
				group 2: general: (0.4±0.7/-/-)	Group 2: 30 teeth 0 mm: 0 (0%) 0.5 mm: 23 (76.7%) 1 mm: 4 (13.3%) 1.5 mm: 3 (10%) 2 mm: 0 (0%) 2.5 mm:0 (0%) 3 mm: 0 (0%)	
Martins DR, 2012	Brazil	56 patients Group 1: 28 Group 2: 28	2D	Group 1: general (2.37/-/-)	Total: 0: 0 (0%) 1: 62 (27.67%) 2: 97 (43.30%) 3: 58 (25.89%) 4: 7 (3.13%) Group 1: 16.95% no EARR / 83.04% EARR 0: 0 (0%) 1: 19 (16.96%) 2: 39 (34.83%) 3: 47 (41.96%) 4: 7 (6.25%)	Fixed appliances
				Group 2: general (1.69/-/-)	Group 2: 38.39% EARR / 61.61% no EARR 0: 0(0%) 1: 43 (38.39%) 2: 58 (51.78%) 3: 11 (9.83%) 4: 0 (0%)	
Dermaut 1986	Belgium	20 patients	2D	general: (-/-/2.5)	Mean root resorption of 18% of each teeth Experimental: 0.6ratio: 2 0.7ratio: 10 0.8ratio: 23 0.9ratio: 22 1ratio: 8 1.1ratio: 1 1.2ratio: 0 Control: 0.6 ratio: 0 0.7 ratio: 0 0.8 ratio: 3 0.9 ratio: 12 1 ratio: 25 1.1 ratio: 17 1.2 ratio: 1	Fixed appliances
Thomas E, 2011	India	68 patients Group 1: 26 Group 2: 23 Group 3: 19	2D	Group 1: Tip-edge central (1.315±1.071/-/-) Group 2: Modified edgewise central: (1.607±0.954/-/-) Group 3: Damon central: (2.282±1.828/-/-)	Total: 68 patients-68 teeth 0: 5 (7.35%) 1: 34 (50%) 2: 23 (33.8%) 3: 6 (8.82%)	Fixed appliances
Horiuchi E, 1998	Japan	146 patients	2D	-	less than 1 mm: 9% of the patients more than 3 mm: 22% of the patients	Fixed appliances
Levander E, 1998	Sweden	45 patients 92 teeth	2D	3 months: 0.3±0.3 mm ordinary risk: (0.2±0.2/-/-) 6 months: 0.6±0.5 mm ordinary risk: (0.8±0.6/-/-)	TOTAL (n=92 teeth) <0.5 mm: 45 teeth 0.5-0.9 mm: 25 teeth 1-1.4 mm: 15 teeth >1.5 mm: 7 teeth ORDINARY RISK (n=56 teeth) <0.5 mm: 34 teeth 0.5-0.9 mm: 17 teeth 1-1.4 mm: 3 teeth >1.5 mm: 2 teeth	Fixed appliances
				3 months: 0.3±0.3/-/- enhanced risk: (0.5±0.4/-/-) 6 months: 0.6±0.5/-/- enhanced risk: (0.4±0.4/-/-)	ENHANCED RISK (n=36 teeth) <0.5 mm: 11 teeth 0.5-0.9 mm: 8 teeth 1-1.4 mm: 12 teeth >1.5 mm: 5 teeth	
Reukers EAJ, 1998	The Netherlands	61 patients FPA: 32 patients PPA: 29 patients	2D	FPA (fully programed edgewise): central: (-/-/8.2±6.4) PPA (partly programmed edgewise: central: (-/-7.5±7.6)	FPA: 24/32 (75%) PPA: 16/29 (55%)	Fixed appliances

Alexander SA, 1996	USA	56 patients	2D	Full arch: (0.33±0.07/-/-) Central: (0.27±0.06/-/-) Lateral: (0.39±0.07/-/-)	Full arch: CI: 12/56 (21%) LI: 14/56 (25%)	Fixed appliances
				sectional arch: (0.33±0.08/-/-) Central: (0.29±0.08/-/-) Lateral: (0.35±0.11/-/-)	Sectional arch: CI: 9/56 (16%) LI: 15/56 (27%)	
Preoteasa CT, 2009	Bucharest	50 patients	2D	-	Lateral: 0: 12(24%); 1: 22(44%); 16(32%); 3:0(0%) Central: 0: 13(26%); 1: 27 (54%); 2: 10(20%); 3: 0 (0%) FIXED APPLIANCES: 76.7% (230 teeth) have EARR Patients 0: 1 (4%) 1: 3 (12%) 2: 18 (72%) 3: 3 (12%) Teeth 0: 70 (23%) 1: 150 (50%) 2: 77 (26%) 3: 3 (1%) REMOVABLE 0: 100%	Fixed appliances Removable appliances
Janson GRP, 1999	Brazil	90 patients Gr1: 30 Gr2: 30 Gr3: 30	2D	Central: (-/-/1.7) Lateral: (-/-/1.65)	0: 2.25% 1: 42.56% 2: 53.37% 3: 1.40% 4: 0.42%	Fixed appliances
Makedonas D, 2013	Sweden	156 patients	3D	-	Central: score 2: 31.4%; score 3: 8.7%; score 4: 0.6% Lateral: score 2: 41%; score 3: 10.3%; score 4: 0.6% 12: 2: 70; 3: 16; 4: 1 11: 2: 53; 3: 15; 4: 1 21: 2: 45; 3: 12; 4: 1 22: 2: 58; 3: 16; 4: 1 General: Score 3 of 25.6%	Fixed appliances
Nasri FAM, 2020	Malaysia	10 patients	2D	general: (0.56±0.30/-/-)	100% mild root resorption (<2 mm)	Fixed appliances
Kaley J, 1991	USA	200 patients	2D	General: (1.17/-/-)	Maxillary central incisor: 21 patients with severe EARR (10.5%) 12: 0: 14%; 1: 47%; 2: 37%; 3: 3% 11: 0: 8%; 1: 45%; 2: 44%; 3: 3% 21: 0:8%; 1: 44%; 2: 43%; 3: 4% 12: 0: 14%; 1: 48%; 2: 36%; 3: 3%	Fixed appliances
Makedonas D, 2011	Sweden	97 patients	3D	-	score 0-1: (92.8%) score 2: (4.4%) score 3: (2.8%) score 4: 0 (0%)	Fixed appliances
Levander E, 1988	Sweden	98 patients (390 incisors)	2D	-	0: 49 1: 82 2: 188 3: 66 4: 5	Fixed appliances
Goldson L, 1975	Sweden	42 patients	2D	-	Completed treatment: central: 89.7% 1: 11.5% 2: 0% 3: 65.4% 4: 1.3% 5: 11.5% lateral: 87% 1: 6.5% 2: 1.3% 3: 68.8% 4: 1.3% 5: 9.1%	Fixed appliances
Scheibel PC, 2014	Brazil	47 patients	2D	central: (-/-/3.5±3.03)	0%: 3 (6%) >1% to <4%: 18 (38%) <4% to <8%: 18 (38%) >8% to <12%: 8 (17%)	Fixed appliances
de Freitas JC, 2013	Brazil	58 patients	2D 3D	-	EARR Central: 93 (80.1%) Lateral: 104 (94.5%)	Fixed appliances
Harris EF, 1992	USA	63 patients (32 open bites and 31 deep bites)	2D	-	open bites: 0: 0 1: 0 2: 15 3: 10 4: 1 deep bites: 0: 3 1: 8 2: 14 3: 5 4: 0	Fixed appliances
Chiqueto K, 2008	Brazil	60 patients	2D	general (1.94/-/-)	general: deep bite: 1.87 mean degree 0: 8 (3.33%) 1: 65 (27.08%) 2: 123 (51.25%) 3: 39 (16.25%) 4: 5 (2.08%) normal bite: 1.54 mean degree 0: 20 (8.33%) 1: 94 (39.17%) 2: 102 (42.5%) 3: 24 (10%) 4: 0 (0%)	Fixed appliances
Alemam AA, 2019	Jordan	51 patients	3D	-	25.5% of 51 patients	Fixed appliances
Maués CPR, 2015	Brazil	129 patients (959 teeth)	2D	-	maxillary incisors: 94,5% (451) No EARR (0-3 degree) 5,5% (26) EARR (4 degree)	Fixed appliances
Ramos SP, 2011	Brazil	50 patients	2D	-	0: 18 (36%) 1: 24 (48%) 2: 8 (16%)	Fixed appliances
Han J, 2019	Korea USA Japan	39 patients	2D	Young central: (0.6±0.44/-/-) Middle adults central: (1±0.61/-/-)	<1 mm: 15 patients - 88.2% (young) and 22 patients - 59.5% (middle adults) ≥1 to <2 mm: 2 patients - 11.8% (young) and 11 patients - 29.7% (middle adults) >2 mm to <3 mm: 0 - 0 % (young) and 4 patients - 10.8% (middle adults)	Fixed appliances
Lupi JE, 1996	USA	88 patients	2D	-	TOTAL: 0: 170 1: 318 2: 145 3:13 Central: 0: 39 1: 77 2: 46 3: 4 Lateral: 0: 39 1:81 2: 33 3: 8	Fixed appliances
Sharab Y, 2015	USA	460 patients	2D	-	14.56% 67patients (affected: at least 1 incisor with 3 or 4 Malmgren)	Fixed appliances
Mavragani M, 2002	Norway	80 patients treated vs 66 non treated	2D	11: (1.82±0.26/-/-) 21: (1.93±0.25/-/-) 12: (1.86±0.26/-/-) 22: (1.78±0.33/-/-)	50 teeth with EARR of 280	Fixed appliances
Lee YJ, 2022	South Korea	118 patients	2D	general: (2.9±2.4/-/-) affected: (4.8±1.8/-/-) unaffected: (0.9±0.6/-/-)	59 affected patients (50%) 59 unaffected patients (50%)	Fixed appliances
Fernandes LQ, 2019	Brazil	564 patients	2D	-	37.3% EARR ≥2 mm (810 teeth)	Fixed appliances
Ciurla A, 2021	Poland	101 patients	2D	-	General EARR: 39.60% No EARR: 60.40%	Fixed appliances
Shahrure B, et al	Türkiye	7000 patients	2D	-	Severe EARR: 3.23% (120 patients) mild/moderate EARR: 96.77%	Fixed appliances
Futyma-Gąbka K, 2022	Poland	194 patients	2D	-	146 patients with EARR variable stage of EARR (canines included) 12: I: 28 / II: 54 / III: 20 / IV: 1 11: I: 32 / II: 55 / III: 23 / IV: 5 21: I: 26 / II: 52 / III: 22 / IV: 6 22: I: 25 / II: 61 / III: 20 / IV: 1	Fixed appliances
Zawawi KH, 2014	Saudi Arabia	40 patients	2D	both groups: central: (0.99±0.11/-/-) conventional: central: (0.86±0.05/-/-) bidimensional: central: (1.11±0.17/-/-)	Bidimensional group: 35% of EARR Conventional group: 30% of EARR both groups: no EARR: 26 (32.5%) mild: 45 (56.2%) moderate: 7 (8.8%) severe: 2 (2.5%)	Fixed appliances
Aman A, 2018	USA	160 patients	3D	central: (0.53±0.59/-/3.72±4.08) 11: (0.50±0.61/-/4.03±4.77) 21: (0.55±0.70/-/4.30±5.31) lateral: (0.49±0.57/-/4.16±4.50) 12: (0.47±0.61/-/3.60±4.50) 22: (0.51±0.70/-/3.87±4.95)	1.25% has severe EARR	Removable appliances
Barros SE, 2017	Brazil	37 patients group 1: 22 group 2: 15	2D	-	group 1 (no skeletal anchorage) group 2 (skeletal anchorage)	Fixed appliances
Al-Qawasmi RA, 2003	USA	106 patients	2D	-	33 EARR (>2 mm) 73 no EARR	Fixed appliances
Bayir F, 2021	Türkiye	1356 patients	2D		General No and mild: 85.2% Moderate and severe: 14.8%	Fixed appliances
Johansson K, 2025	Sweden	62 patients (Damon): 30 (Victory): 32	3D	Damon: total (0.2±1.12/-/-) central: 11: (0.44±1.48/-/-) 21: (0.10±1.05/-/-) lateral: 12: (0.16±0.98/-/-) 22: (0.11±0.91/-/-)	Damon: no EARR or mild: 96.25% moderate and severe: 3.75%	Fixed appliances
				Victory: total (0.51±1.03/-/-) central: 11: (0.31±0.90/-/-) 21: (0.40±0.87/-/-) lateral: 12: (0.71±0.90/-/-) 22: (0.62±1.37/-/-)	Victory: no EARR or mild: 95.38% moderate and severe: 4.62%	Fixed appliances
Litchfield IV FE, 2024	USA	336 patients	2D	-	>2 mm: central: 36.4% (120) lateral: 35.1% (111)	Fixed appliances
Sambale J, 2024	Germany	1156 patients	2D	-	grade 2 and 3 (<2 mm): central: 11: 6.14% (71) 21: 5.27% (61) lateral: 12: 6.22% (72) 22: 6.22% (72)	Fixed appliances
Chandorikar WA, 2022	India	52 patients MT: 26 no MT: 26	3D	gr1: control group (No MT) centrals: (0.72±0.21/-/-) laterals: (0.75±0.18/-/-)	general: no EARR: 45% EARR: 55%	Fixed appliances
				gr2: MT centrals: (0.79±0.23/-/-) laterals: (0.82±0.3/-/-)		

EARR, external apical root resorption.

Supplementary File 1. Search string

PUBMED:

((((((((((((((((((((((root resorption[MeSH Terms]) OR (root resorptions[MeSH Terms])) OR ("root resorption"[tiab])) OR ("root resorptions"[tiab])) OR ("EARR"[tiab])) OR ("OIRR"[tiab])) OR ("apical root resorption"[tiab])) OR ("external root resorption"[tiab])) OR (tooth resorption[MeSH Terms])) OR ("tooth resorption"[tiab])) OR (tooth resorptions[MeSH Terms])) OR ("tooth resorptions"[tiab])) OR ("teeth resorption"[tiab])) OR ("root shortening"[tiab])) OR ("teeth shortening"[tiab])) OR (OIIRR [tiab])) OR (ORR [tiab])) OR (ARR [tiab])) OR (RR [tiab])) OR (ERR [tiab])) OR (OIEARR [tiab])) OR (OIERR [tiab])) AND (((((((((((((((("orthodontic appliances"[MeSH Terms]) OR ("orthodontic appliance"[tiab])) OR ("orthodontic treatment"[tiab])) OR ("fixed appliances"[tiab])) OR (orthodontic bracket[MeSH Terms])) OR ("orthodontic bracket"[tiab])) OR ("orthodontic forces"[tiab])) OR ("orthodontic movement"[tiab])) OR (tooth movement[MeSH Terms])) OR ("tooth movement"[tiab])) OR ("teeth movement"[tiab])) OR (orthodontic bracket[MeSH Terms])) OR ("bracket"[tiab])) OR ("braces"[tiab])) OR ("clear aligners"[tiab])) OR ("invisalign"[tiab])) OR ("aligner"[tiab]))) NOT ((((((((((((((((((((((animal model[MeSH Terms]) OR ("animal model"[tiab])) OR ("invitro"[tiab])) OR ("in-vitro"[tiab])) OR (animal experiment[MeSH Terms])) OR ("animal experiment"[tiab])) OR (dog[MeSH Terms])) OR ("dog"[tiab])) OR ("mouse"[tiab])) OR ("mice"[tiab])) OR ("rat"[tiab])) OR ("rats"[tiab])) OR ("endodontic"[tiab])) OR ("trauma"[tiab])) OR (retreatment[MeSH Terms])) OR ("retreatment"[tiab])) OR (cleft palate[MeSH Terms])) OR ("cleft palate"[tiab])) OR ("syndrome"[tiab])) OR (deciduous dentition[MeSH Terms])) OR (deciduous teeth[MeSH Terms])) OR ("avulsion"[tiab])) OR (avulsed tooth[MeSH Terms])) OR ("avulsed"[tiab]))

SCOPUS:

(root resorption OR root resorptions OR EARR OR OIRR OR apical root resorption OR external root resorptionOR tooth resorption OR tooth resorptions OR teeth resorption OR root shortening OR teeth shortening OR OIIRR OR ORR OR ARR OR RR OR ERR OR OIEARR OR OIERR) AND (orthodontic appliances OR orthodontic appliance OR orthodontic treatment OR fixed appliances OR orthodontic bracket OR orthodontic forces OR orthodontic movement OR tooth movement OR teeth movement OR bracket OR braces OR clear aligners OR invisalign OR aligner) AND NOT (animal model OR invitro OR in-vitro OR animal experiment OR dog OR mouse OR mice OR rat OR dogs OR rats OR endodontic OR trauma OR retreatment OR cleft palate OR syndrome OR deciduous dentition OR avulsion OR avulsed teeth OR avulsed tooth)

WOS

1.((((((((((((((TS=(EARR)) OR TS=("root resorption")) OR TS=(OIRR)) OR TS=(OIIR)) OR TS=("apical root resorption)) OR TS=("tooth resorption")) OR TS=(ORR)) OR TS=(OIIRR)) OR TS=(ARR)) OR TS=(ERR)) OR TS=(OIEAR)) OR TS=(OIERR)) OR TS=("teeth resorption")) OR TS=("tooth shortening")) OR TS=("root shortening")

2.((((((((((((TS=("orthodontic appliances")) OR TS=("orthodontic appliance")) OR TS=("orthodontic treatment")) OR TS=("fixed appliances")) OR TS=("orthodontic bracket")) OR TS=("orthodontic forces")) OR TS=("orthodontic movement")) OR TS=("tooth movement")) OR TS=("teeth movement")) OR TS=(bracket)) OR TS=(braces)) OR TS=("clear aligners")) OR TS=(invisalign)) OR TS=(aligner)

3.(((((((((((((((((TS=("animal model)) OR TS=("animal experiment")) OR TS=(invitro)) OR TS=(in-vitro)) OR TS=(dog)) OR TS=(mouse)) OR TS=(mice)) OR TS=(rat)) OR TS=(dogs)) OR TS=(rats)) OR TS=(endodontic)) OR TS=(trauma)) OR TS=(retreatment)) OR TS= ("cleft palate")) OR TS=(syndrome)) OR TS=("deciduous dentition")) OR TS=("avulsed teeth")) OR TS=("avulsed tooth")) OR TS=(avulsion)

#1 AND #2 NOT #3 (MeSH Headings)

SCIELO

((EARR) OR ("root resorption") OR (OIRR) OR ("apical root resorption") OR (OIIR) OR ("apical root resorption") OR ("tooth resorption") OR (ORR)) OR (OIIRR) OR (ARR)OR (ERR) OR (OIEAR) OR (OIERR) OR ("teeth resorption") OR ("root shortening") OR ("tooth shortening"))AND (("orthodontic appliance*") OR ("orthodontic treatment") OR ("fixed appliances") OR ("orthodontic bracket") OR ("orthodontic forces") OR ("orthodontic. movement") OR ("tooth movement") OR ("teeth movement") OR (bracket*) OR (braces) OR ("clear aligners") OR (invisalign) OR (aligner)) NOT (("animal model") OR ("animal. experiment") OR (invitro) OR (in-vitro) OR (dog*) OR (rat*) OR (mouse) OR (mice) OR (endodontic) OR (trauma) OR (retreatment) OR ("cleft palate") OR (syndrome) OR ("deciduous dentition") OR ("avulsed teeth") OR ("avulsed tooth") OR (avulsion))

Supplementary File 2. Reasons for exclusion of articles

1.Inadequate outcome:

-Leite V, Conti AC, Navarro R, Almeida M, Oltramari-Navarro P, Almeida R. Comparison of root resorption between self-ligating and conventional preadjusted brackets using cone beam computed tomography. Angle Orthod. 2012 Nov;82(6):1078-1082. doi: 10.2319/080911-501.1.

-Fritz U, Rudzki-Janson I, Paschos E, Diedrich P. Light microscopic and SEM findings after orthodontic treatment--analysis of a human specimen. J Orofac Orthop. 2005;66(1):39-53. doi: 10.1007/s00056-005-0434-3.

-Linhartova P, Cernochova P, Kastovsky J, Vrankova Z, Sirotkova M, Holla L. Genetic determinants and postorthodontic external apical root resorption in Czech children. Oral Dis. 2017;23(1):29-35. doi: 10.1111/odi.12564.

-Silva AC, Capistrano A, Almeida-Pedrin RR, Cardoso MA, Conti AC, Capelozza L. Root length and alveolar bone level of impacted canines and adjacent teeth after orthodontic traction: a long-term evaluation. J Appl Oral Sci. 2017;25(1):75-81. doi: 10.1590/1678-77572016-0133.

-Yamaguchi M, Aihara N, Kojima T, Kasai K. RANKL increase in compressed periodontal ligament cells from root resorption. J Dent Res. 2006;85(8):751-756. doi: 10.1177/154405910608500812.

-Ousehal L, Lazrak L, Essmaali FE, Ngom PI. Apical root resorption in patients wearing orthodontic appliances. Odontostomatol Trop. 2012;35(139):12-18.

-Górniak E. Resorpcja cementu korzeniowego w pomiarach wskaźników resorpcji [Resorption of root cement studied with resorption indices]. Ann Acad Med Stetin. 2006;52(2):99-105.

-Lin YJ, Yan JY, Wang TG, Zhou ZJ, Mao LX, Liu JQ. [Cone-beam CT measurement of morphological changes of the root and alveolar bone of the central incisor during orthodontic treatment with extraction]. Shanghai Kou Qiang Yi Xue. 2022;31(2):211-216.

2.Periodontally affected or endodontically treated teeth.:

-Zasčiurinskienė E, Lund H, Lindsten R, Jansson H, Bjerklin K. Outcome of periodontal-orthodontic treatment in subjects with periodontal disease. Part II: a CBCT study of alveolar bone level changes. Eur J Orthod. 2019;41(6):565-574. doi: 10.1093/ejo/cjz039.

-Llamas-Carreras JM, Amarilla A, Solano E, Velasco-Ortega E, Rodríguez-Varo L, Segura-Egea JJ. Study of external root resorption during orthodontic treatment in root filled teeth compared with their contralateral teeth with vital pulps. Int Endod J. 2010;43(8):654-662. doi: 10.1111/j.1365-2591.2010.01722.x.

3.The data does not display independently for upper incisors:

-Motokawa M, Sasamoto T, Kaku M, et al. Association between root resorption incident to orthodontic treatment and treatment factors. Eur J Orthod. 2012;34(3):350-356. doi: 10.1093/ejo/cjr018.

-de Freitas MR, Beltrão RT, Janson G, Henriques JF, Chiqueto K. Evaluation of root resorption after open bite treatment with and without extractions. Am J Orthod Dentofacial Orthop. 2007;132(2):143.e15-22. doi: 10.1016/j.ajodo.2006.10.018.

-Odenrick L, Brattström V. Nailbiting: frequency and association with root resorption during orthodontic treatment. Br J Orthod. 1985;12(2):78-81. doi: 10.1179/bjo.12.2.78.

-Hollender L, Rönnerman A, Thilander B. Root resorption, marginal bone support and clinical crown length in orthodontically treated patients. Eur J Orthod. 1980;2(4):197-205. doi: 10.1093/ejo/2.4.197-a.

-Odenrick L, Brattström V. The effect of nailbiting on root resorption during orthodontic treatment. Eur J Orthod. 1983;5(3):185-188. doi: 10.1093/ejo/5.3.185.

-Armstrong D, Kharbanda OP, Petocz P, Darendeliler MA. Root resorption after orthodontic treatment. Aust Orthod J. 2006;22(2):153-160

-Jiang RP, McDonald JP, Fu MK. Root resorption before and after orthodontic treatment: a clinical study of contributory factors. Eur J Orthod. 2010;32(6):693-7. doi: 10.1093/ejo/cjp165.

-Sebbar M, Bourzgui F. Résorption radiculaire et traitement orthodontique [Root resorption and orthodontic treatment]. Odontostomatol Trop. 2011;34(135):43-50.

-Ge LL, Lyu Q, Bai X, Wu SH, Jiang XL. [Comparison of apical root resorption of maxillary incisors between adolescents and adults after orthodontic treatment]. Shanghai Kou Qiang Yi Xue. 2021;30(2):187-190.

-Tian YL, Wang K, Wang J, Liu F, Piao ML. [Root resorption after orthodontic treatment: a study of age factor and prevalence in anterior teeth]. Shanghai Kou Qiang Yi Xue. 2013 Apr;22(2):224-227.

4.TADs:

-Santos GD, Consolaro A, Meloti F, et al. Negligible tooth resorptions after anterior open bite treatment using skeletal anchorage with miniplates. Dental Press J Orthod. 2020;25(4):16-22. doi: 10.1590/2177-6709.25.4.016-022.oin.

5.Literature review:

-Fox N. Longer orthodontic treatment may result in greater external apical root resorption. Evid Based Dent. 2005;6(1):21. doi: 10.1038/sj.ebd.6400304.

6.Case study:

-Imamura T, Uesugi S, Ono T. Unilateral maxillary central incisor root resorption after orthodontic treatment for Angle Class II, division 1 malocclusion with significant maxillary midline deviation: A possible correlation with root proximity to the incisive canal. Korean J Orthod. 2020;50(3):216-226. doi: 10.4041/kjod.2020.50.3.216.

7.Anomalous teeth:

-Thongudomporn U, Freer TJ. Anomalous dental morphology and root resorption during orthodontic treatment: a pilot study. Aust Orthod J. 1998;15(3):162-167

8.Preselected patients with EARR:

-Kaczor-Urbanowicz KE, Deutsch O, Zaks B, Krief G, Chaushu S, Palmon A. Identification of salivary protein biomarkers for orthodontically induced inflammatory root resorption. Proteomics Clin Appl. 2017;11(9-10). doi: 10.1002/prca.201600119.

-Levander E, Malmgren O. Long-term follow-up of maxillary incisors with severe apical root resorption. Eur J Orthod. 2000;22(1):85-92. doi: 10.1093/ejo/22.1.85.

-Zhang X, Li MQ, Guo J, Yang HW, Yu J, Li GJ. An analysis of the optimal intrusion force of the maxillary central incisor with root horizontal resorption using the finite element method and curve fitting. Comput Methods Biomech Biomed Engin. 2022;25(13):1471-1486. doi: 10.1080/10255842.2021.2017904.

-Mohd Zain MN, Md Yusof Z, Basri KN, et al. Multivariate versus univariate spectrum analysis of dentine sialophosphoprotein (DSPP) for root resorption prediction: a clinical trial. BMC Oral Health. 2022;22(1):151. doi: 10.1186/s12903-022-02178-2.

9.No access to the full article:

-Wang YL, Wang TJ, Liu ZH. [Changes in root and alveolar bone before and after treatment by retracting the upper incisors]. Hua Xi Kou Qiang Yi Xue Za Zhi. 2018;36(6):638-645. doi: 10.7518/hxkq.2018.06.011. Chinese.

-Wang G, Yang L, Zhang YF, Luo SL, Zheng JW. [A retrospective study on incisor root resorption in patients treated with bracketless invisible appliance and straight wire appliance]. Shanghai Kou Qiang Yi Xue. 2017;26(1):121-124. Chinese.

-Chen W, Chen RJ. [Effect of high pull J hook headgear on root resorption during orthodontic treatment]. Shanghai Kou Qiang Yi Xue. 2005;14(4):345-7. Chinese

-Zhang J, Zhang WJ, Wang XX, Ma SL, Chen DY. [Correlation study between sex and age of patients and root resorption after orthodontic treatment]. Shanghai Kou Qiang Yi Xue. 2005;14(5):452-455. Chinese.

-Martel D. External apical root resorption and fixed orthodontic tooth movement. Int J Orthod Milwaukee. 2009;20:39-40.

-Morse PH. Resorption of upper incisors following orthodontic treatment. Dent Pract Dent Rec. 1971;22(1):21-35.

-Bau DJ. Root resorption during orthodontic treatment. Aust Orthod J. 2003;19(2):3A.

-Jiang RP, Zhang D, Fu MK. [A factors study of root resorption after orthodontic treatment]. Zhonghua Kou Qiang Yi Xue Za Zhi. 2003;38(6):455-457. Chinese.

Supplementary File 3. References for the studies included in Supplementary Table 1.

- Li Y, Deng S, Mei L, et al. Prevalence and severity of apical root resorption during orthodontic treatment with clear aligners and fixed appliances: a cone beam computed tomography study. Prog Orthod. 2020;21(1):1. doi: 10.1186/s40510-019-0301-1.
- Wichelhaus A, Dulla M, Sabbagh H, Baumert U, Stocker T. Stainless steel and NiTi torque archwires and apical root resorption. J Orofac Orthop. 2021;82(1):1–12. doi: 10.1007/s00056-020-00244-4.
- Pamukçu H, Polat-Özsoy Ö, Gülşahi A, Özemre MÖ. External apical root resorption after nonextraction orthodontic treatment with labial vs. lingual fixed appliances. J Orofac Orthop. 2020;81(1):41–51. doi: 10.1007/s00056-019-00201-w.
- Gay G, Ravera S, Castroflorio T, et al. Root resorption during orthodontic treatment with Invisalign®: a radiometric study. Prog Orthod. 2017;18(1):12. doi: 10.1186/s40510-017-0166-0.
- Ciurla A, Szymańska J, Płachno BJ, Bogucka-Kocka A. Polymorphisms of Encoding Genes IL1RN and P2RX7 in Apical Root Resorption in Patients after Orthodontic Treatment. Int J Mol Sci. 2021;22(2):777. doi: 10.3390/ijms22020777.
- Neves BMD, Fernandes LQP, Capelli Junior J. External apical root resorption after orthodontic treatment: analysis in different chronological periods. Dent Press J Orthod. 2022;27(5):e2220100. doi: 10.1590/2177-6709.27.5.e2220100.oar.
- Janson G, Niederberger A, Garib DG, Caldas W. Root resorption in Class II malocclusion treatment with Class II elastics. Am J Orthod Dentofacial Orthop. 2016;150(4):585–591. doi: 10.1016/j.ajodo.2016.02.031.
- Liu W, Shao J, Li S, et al. Volumetric cone-beam computed tomography evaluation and risk factor analysis of external apical root resorption with clear aligner therapy. Angle Orthod. 2021;91(5):597–603. doi: 10.2319/111820-943.1.
- Linhartova P, Cernochova P, Holla L. IL1 gene polymorphisms in relation to external apical root resorption concurrent with orthodontia. Oral Dis. 2013;19(3):262–270. doi: 10.1111/j.1601-0825.2012.01973.x.
- Da-Costa TMPS, Hidalgo MM, Consolaro A, Lima CEDO, Tanaka EO, Itano EN. External apical root resorption diagnosis by using FII human dentine fraction and salivary IGg. Int Orthod. 2018;16(2):258–267. doi: 10.1016/j.ortho.2018.03.015.
- Jyotirmay, Singh SK, Adarsh K, Kumar A, Gupta AR, Sinha A. Comparison of Apical Root Resorption in Patients Treated with Fixed Orthodontic Appliance and Clear Aligners: A Cone-beam Computed Tomography Study. J Contemp Dent Pract. 2021;22(7):763–768.
- Sepanian V, Sonnesen L. Incisor root resorption in class II division 2 patients in relation to orthodontic treatment. Eur J Orthod. 2018;40(3):337–342. doi: 10.1093/ejo/cjx086.
- Handem RH, Janson G, Matias M, et al. External root resorption with the self-ligating Damon system—a retrospective study. Prog Orthod. 2016;17(1):20. doi: 10.1186/s40510-016-0133-1.
- Iglesias-Linares A, Yañez-Vico R, Ballesta-Mudarra S, et al. Postorthodontic external root resorption is associated with IL1 receptor antagonist gene variations: Root resorption and interleukin 1 receptor antagonist. Oral Dis. 2012;18(2):198–205. doi: 10.1111/j.1601-0825.2011.01865.x.
- Krieger E, Drechsler T, Schmidtmann I, Jacobs C, Haag S, Wehrbein H. Apical root resorption during orthodontic treatment with aligners? A retrospective radiometric study. Head Face Med. 2013;9(1):21. doi: 10.1186/1746-160X-9-21.
- Iglesias-Linares A, Yañez-Vico R, Moreno-Fernández A, Mendoza-Mendoza A, Orce-Romero A, Solano-Reina E. Osteopontin gene SNPs (rs9138, rs11730582) mediate susceptibility to external root resorption in orthodontic patients. Oral Dis. 2014;20(3):307–312. doi: 10.1111/odi.12114.
- Picanço GV, Freitas KMSD, Cançado RH, Valarelli FP, Picanço PRB, Feijão CP. Predisposing factors to severe external root resorption associated to orthodontic treatment. Dent Press J Orthod. 2013;18(1):110–120. doi: 10.1590/s2176-94512013000100022.
- Jacobs C, Gebhardt PF, Jacobs V, Hechtner M, Meila D, Wehrbein H. Root resorption, treatment time and extraction rate during orthodontic treatment with self-ligating and conventional brackets. Head Face Med. 2014;10(1):2. doi: 10.1186/1746-160X-10-2.
- Qin F, Zhou Y. The influence of bracket type on the external apical root resorption in class I extraction patients - a retrospective study. BMC Oral Health. 2019;19(1):53. doi: 10.1186/s12903-019-0743-3.
- Iglesias-Linares A, Sonnenberg B, Solano B, et al. Orthodontically induced external apical root resorption in patients treated with fixed appliances vs removable aligners. Angle Orthod. 2017 J;87(1):3–10. doi: 10.2319/02016-101.1.
- Rakhshan V, Nateghian N, Ordoubazari M. Risk factors associated with external apical root resorption of the maxillary incisors: a 15-year retrospective study. Aust Orthod J. 2012;28(1):51-56.
- Ramanathan C, Hofman Z. Root resorption during orthodontic tooth movements. Eur J Orthod. 2009;31(6):578–583. doi: 10.1093/ejo/cjp058.
- Al-Qawasmi RA, Hartsfield JK, Everett ET, et al. Genetic predisposition to external apical root resorption. Am J Orthod Dentofacial Orthop. 2003;123(3):242–252. doi: 10.1067/mod.2003.42.
- Castro IO, Alencar AHG, Valladares-Neto J, Estrela C. Apical root resorption due to orthodontic treatment detected by cone beam computed tomography. Angle Orthod. 2013;83(2):196–203. doi: 10.2319/032112-240.1.
- Årtun J, Van 'T Hullenaar R, Doppel D, Kuijpers-Jagtman AM. Identification of orthodontic patients at risk of severe apical root resorption. Am J Orthod Dentofacial Orthop. 2009;135(4):448–455. doi: 10.1016/j.ajodo.2007.06.012.
- Apajalahti S, Peltola JS. Apical root resorption after orthodontic treatment a retrospective study. Eur J Orthod. 2007;29(4):408–412. doi: 10.1093/ejo/cjm016.
- Lund H, Gröndahl K, Hansen K, Gröndahl HG. Apical root resorption during orthodontic treatment: A prospective study using cone beam CT. Angle Orthod. 2012;82(3):480–487. doi: 10.2319/061311-390.1.
- Maurya R, Bhardwaj P, Singh H, Mishra H. Comparative evaluation of duration of extraction space closure and degree of root resorption with conventional and self-Ligation brackets. Indian J Dent Res. 2022;33(1):52–57. doi: 10.4103/ijdr.ijdr_1127_21.
- Nigul K, Jagomagi T. Factors related to apical root resorption of maxillary incisors in orthodontic patients. Stomatologija. 2006;8(3):76-79.
- Elhaddaoui R, Benyahia H, Azeroual MF, Zaoui F, Razine R, Bahije L. Resorption of maxillary incisors after orthodontic treatment – clinical study of risk factors. Int Orthod. 2016;14(1):48–64. doi: 10.1016/j.ortho.2015.12.015.
- Marques LS, Ramos-Jorge ML, Rey AC, Armond MC, Ruellas AC. Severe root resorption in orthodontic patients treated with the edgewise method: Prevalence and predictive factors. Am J Orthod Dentofacial Orthop. 2010;137(3):384–388. doi: 10.1016/j.ajodo.2008.04.024.
- Mohandesan H, Ravanmehr H, Valaei N. A radiographic analysis of external apical root resorption of maxillary incisors during active orthodontic treatment. Eur J Orthod. 2007;29(2):134–139. doi: 10.1093/ejo/cjl090.
- Artun J, Smale I, Behbehani F, Doppel D, Van't Hof M, Kuijpers-Jagtman AM. Apical root resorption six and 12 months after initiation of fixed orthodontic appliance therapy. Angle Orthod. 2005;75(6):919-926. doi: 10.1043/0003-3219(2005)75[919:ARRSAM]2.0.CO;2.

- Motokawa M, Terao A, Kaku M, et al. Open bite as a risk factor for orthodontic root resorption. Eur J Orthod. 2013;35(6):790–795. doi: 10.1093/ejo/cjs100.
- Chen W, Haq AAA, Zhou Y. Root resorption of self-ligating and conventional preadjusted brackets in severe anterior crowding Class I patients: a longitudinal retrospective study. BMC Oral Health. 2015;15(1):115. doi: 10.1186/s12903-015-0100-0.
- Dudic A, Giannopoulou C, Leuzinger M, Kiliaridis S. Detection of apical root resorption after orthodontic treatment by using panoramic radiography and cone-beam computed tomography of super-high resolution. Am J Orthod Dentofacial Orthop. 2009;135(4):434–437. doi: 10.1016/j.ajodo.2008.10.014.
- Remington DN, Joondeph DR, Artun J, Riedel RA, Chapko MK. Long-term evaluation of root resorption occurring during orthodontic treatment. Am J Orthod Dentofacial Orthop. 1989;96(1):43-46. doi: 10.1016/0889-5406(89)90227-8.
- Van Loenen M, Dermaut LR, Degrieck J, De Pauw GA. Apical root resorption of upper incisors during the torquing stage of the tip-edge technique. Eur J Orthod. 2007;29(6):583–588. doi: 10.1093/ejo/cjm060.
- Levander E, Malmgren O, Stenback K. Apical root resorption during orthodontic treatment of patients with multiple aplasia: a study of maxillary incisors. Eur J Orthod. 1998;20(4):427–434. doi: 10.1093/ejo/20.4.427.
- Beck BW, Harris EF. Apical root resorption in orthodontically treated subjects: Analysis of edgewise and tight wire mechanics. Am J Orthod Dentofacial Orthop. 1994;105(4):350-361. doi: 10.1016/S0889-5406(94)70129-6.
- Levander E, Malmgren O, Eliasson S. Evaluation of root resorption in relation to two orthodontic treatment regimes. A clinical experimental study. Eur J Orthod. 1994;16(3):223–228. doi: 10.1093/ejo/16.3.223.
- Martins DR, Tibola D, Janson G, Torres Maria FR. Effects of intrusion combined with anterior retraction on apical root resorption. Eur J Orthod. 2012;34(2):170–175. doi: 10.1093/ejo/cjq178.
- Dermaut LR, De Munck A. Apical root resorption of upper incisors caused by intrusive tooth movement: A radiographic study. Am J Orthod Dentofacial Orthop. 1986;90(4):321–326. doi: 10.1016/0889-5406(86)90088-0.
- Thomas E, Evans W, Piet B. An evaluation of root resorption after orthodontic treatment. SADJ. 2013;67:384-389.
- Horiuchi A, Hotokezaka H, Kobayashi K. Correlation between cortical plate proximity and apical root resorption. Am J Orthod Dentofacial Orthop. 1998;114(3):311–318. doi: 10.1016/s0889-5406(98)70214-8.
- Levander E. Early radiographic diagnosis of apical root resorption during orthodontic treatment: a study of maxillary incisors. Eur J Orthod. 1998;20(1):57–63. doi: 10.1093/ejo/20.1.57.
- Reukers E, Sanderink G, Kuijpers-Jagtman AM, Van'T Hof M. Assessment of apical root resorption using digital reconstruction. Dentomaxillofacial Radiol. 1998;27(1):25–29. doi: 10.1038/sj.dmfr.4600313.
- Alexander SA. Levels of root resorption associated with continuous arch and sectional arch mechanics. Am J Orthod Dentofacial Orthop. 1996;110(3):321–324. doi: 10.1016/s0889-5406(96)80017-5.
- Preoteasa CT, Ionescu E, Preoteasa E, Comes CA, Buzea MC, Grămescu A. Orthodontically induced root resorption correlated with morphological characteristics. Rom J Morphol Embryol. 2009;50(2):257-262.
- Janson GRP, De Luca Canto G, Martins DR, Henriques JFC, De Freitas MR. A radiographic comparison of apical root resorption after orthodontic treatment with 3 different fixed appliance techniques. Am J Orthod Dentofacial Orthop. 2000;118(3):262–273. doi: 10.1067/mod.2000.99136.
- Makedonas D, Lund H, Hansen K. Root resorption diagnosed with cone beam computed tomography after 6 months and at the end of orthodontic treatment with fixed appliances. Angle Orthod. 2013;83(3):389–393. doi: 10.2319/042012-332.1.
- Nasri FA, Zainal Ariffin SH, Karsani SA, Megat Abdul Wahab R. Label-free quantitative proteomic analysis of gingival crevicular fluid to identify potential earsly markers for root resorption. BMC Oral Health. 2020;20(1):256. doi: 10.1186/s12903-020-01246-9.
- Kaley J, Phillips C. Factors related to root resorption in edgewise practice. Angle Orthod. 1991;61(2):125-132. doi: 10.1043/0003-3219(1991)061<0125:FRTRRI>2.0.CO;2.
- Makedonas D, Lund H, Gröndahl K, Hansen K. Root resorption diagnosed with cone beam computed tomography after 6 months of orthodontic treatment with fixed appliance and the relation to risk factors. Angle Orthod. 2012;82(2):196–201. doi: 10.2319/112810-691.1.
- Levander E, Malmgren O. Evaluation of the risk of root resorption during orthodontic treatment: A study of upper incisors. Eur J Orthod. 1988;10(1):30–38. doi: 10.1093/ejo/10.1.30.
- Goldson L, Henrikson CO. Root resorption during Begg treatment: A longitudinal roentgenologic study. Am J Orthod. 1975;68(1):55–66. doi: 10.1016/0002-9416(75)90159-1.
- Scheibel PC, Ramos AL, Iwaki LCV, Micheletti KR. Analysis of correlation between initial alveolar bone density and apical root resorption after 12 months of orthodontic treatment without extraction. Dent Press J Orthod. 2014;19(5):97–102. doi: 10.1590/2176-9451.19.5.097-102.oar.
- Freitas JCD, Lyra OCP, Alencar AHGD, Estrela C. Long-term evaluation of apical root resorption after orthodontic treatment using periapical radiography and cone beam computed tomography. Dent Press J Orthod. 2013;18(4):104–112. doi: 10.1590/s2176-94512013000400015.
- Harris EF, Butler ML. Patterns of incisor root resorption before and after orthodontic correction in cases with anterior open bites. Am J Orthod Dentofacial Orthop. 1992;101(2):112–119. doi: 10.1016/0889-5406(92)70002-R.
- Chiqueto K, Martins DR, Janson G. Effects of accentuated and reversed curve of Spee on apical root resorption. Am J Orthod Dentofacial Orthop. 2008;133(2):261–268. doi: 10.1016/j.ajodo.2006.01.050.
- Alemam AA, Abu Alhaija ES, Mortaja K, AlTawachi A. Incisor root resorption associated with palatally displaced maxillary canines: Analysis and prediction using discriminant function analysis. Am J Orthod Dentofacial Orthop. 2020;157(1):80–90. doi: 10.1016/j.ajodo.2019.08.008.
- Maués CPR, Nascimento RRD, Vilella ODV. Severe root resorption resulting from orthodontic treatment: Prevalence and risk factors. Dent Press J Orthod. 2015;20(1):52–58.doi: 10.1590/2176-9451.20.1.052-058.oar.
- Ramos SDP, Ortolan GO, Dos Santos LM, Tobouti PL, Hidalgo MM, Consolaro A, et al. Anti-dentine antibodies with root resorption during orthodontic treatment. Eur J Orthod. 2011;33(5):584–591. doi: 10.1093/ejo/cjq145.
- Han J, Hwang S, Nguyen T, et al. Periodontal and root changes after orthodontic treatment in middle-aged adults are similar to those in young adults. Am J Orthod Dentofacial Orthop. 2019;155(5):650-655. doi: 10.1016/j.ajodo.2018.05.027.
- Lupi JE, Handelman CS, Sadowsky C. Prevalence and severity of apical root resorption and alveolar bone loss in orthodontically treated adults. Am J Orthod Dentofacial Orthop. 1996;109(1):28–37. doi: 10.1016/s0889-5406(96)70160-9.
- Sharab LY, Morford LA, Dempsey J, et al. Genetic and treatment-related risk factors associated with external apical root resorption (EARR) concurrent with orthodontia. Orthod Craniofac Res. 2015;18:71–82. doi: 10.1111/ocr.12078.
- Mavragani M, Bøe OE, Wisth PJ, Selvig KA. Changes in root length during orthodontic treatment: advantages for immature teeth. Eur J Orthod. 2002;24(1):91–97. doi: 10.1093/ejo/24.1.91.
- Lee YJ,Pak H, Hwang CJ, et al. Targeted next-generation sequencing for comprehensive genetic analysis of external apical root resorption during orthodontic treatment with premolar extraction in Korean population. Am J Orthod Dentofacial Orthop. 2022;162(5):668-679. doi: 10.1016/j.ajodo.2021.06.022.
- Fernandes LQP, Figueiredo NC, Montalvany Antonucci CC, Lages EMB, Andrade I, Capelli Junior J. Predisposing factors for external apical root resorption associated with orthodontic treatment. Korean J Orthod. 2019;49(5):310-318. doi: 10.4041/kjod.2019.49.5.310.
- Ciurla A, Marruganti C, Doldo T, Szymańska J. Association between Polymorphisms in the IL-1β, TNFRSF11B, CASP1, and IL-6 Genes and Orthodontic-Induced External Apical Root Resorption. J Clin Med. 2021;10(18):4166. doi: 10.3390/jcm10184166.
- Shahrani IA, Ajmal M, Alam T, Luqman M, Kamran MA, Mohiy HA. External apical root resorption among the Saudi population: a prospective radiographic study of maxillary and mandibular incisors during orthodontic treatment. J Biol Regul Homeost Agents. 2020;34(1). doi: 10.23812/19-562-L.
- Futyma-Gąbka K, Różyło-Kalinowska I, Piskórz M, Bis E, Borek W. Evaluation of root resorption in maxillary anterior teeth during orthodontic treatment with a fixed appliance based on panoramic radiographs. Pol J Radiol. 2022;87(1):545–548. doi: 10.5114/pjr.2022.120512.
- Zawawi K, Malki G. Radiographic comparison of apical root resorption after orthodontic treatment between bidimensional and Roth straight wire techniques. J Orthod Sci. 2014;3(4):106-110. doi: 10.4103/2278-0203.143229.
- Aman C, Azevedo B, Bednar E, et al. Apical root resorption during orthodontic treatment with clear aligners: A retrospective study using cone-beam computed tomography. Am J Orthod Dentofacial Orthop. 2018;153(6):842–851. doi: 10.1016/j.ajodo.2017.10.026.
- Barros SE, Janson G, Chiqueto K, Baldo VO, Baldo TO. Root resorption of maxillary incisors retracted with and without skeletal anchorage. Am J Orthod Dentofacial Orthop. 2017;151(2):397–406. doi: 10.1016/j.ajodo.2016.06.048.
- Al-Qawasmi RA, Hartsfield JK, Everett ET, et al. Genetic Predisposition to External Apical Root Resorption in Orthodontic Patients: Linkage of Chromosome-18 Marker. J Dent Res. 2003;82(5):356–360. doi: 10.1177/154405910308200506.
- Bayir F, Bolat Gumus E. External apical root resorption after orthodontic treatment: Incidence, severity and risk factors. J Dent Res Dent Clin Dent Prospects. 2021;15(2):100–105. doi: 10.34172/joddd.2021.017.
- Johansson K, Christell H, Brechter A, Paulsson L. Evaluation of External Apical Root Resorption and the Relevance of Intermediate Radiography in Non-Extraction Treatment With Fixed Appliances for Adolescents With Crowding: A Multicenter Randomised Controlled Trial Using CBCT. Orthod Craniofac Res. 2025;28(3):515–526. doi: 10.1111/ocr.12903.
- Litchfield FE, Oster RA, Kau CH, Lamani E. External apical root resorption in African American orthodontic patients. Eur J Orthod. 2024;46(1):cjad059. doi: 10.1093/ejo/cjad059.
- Sambale J, Bruns PM, Jablonski-Momeni A, Heinzel-Gutenbrunner M, Korbmacher-Steiner HM. Prognostic risk factors for apical root resorption in orthodontic patients – Are the Kjær's morphologic characteristics of clinical relevance? Ann Anat. 2024;255:152287. doi: 10.1016/j.aanat.2024.152287.
- Chandorikar H, Bhad WA. Impact of micro-osteoperforations on root resorption and alveolar bone in en-masse retraction in young adults: A CBCT randomized controlled clinical trial. Int Orthod. 2023;21(1):100714. doi: 10.1016/j.ortho.2022.100714.

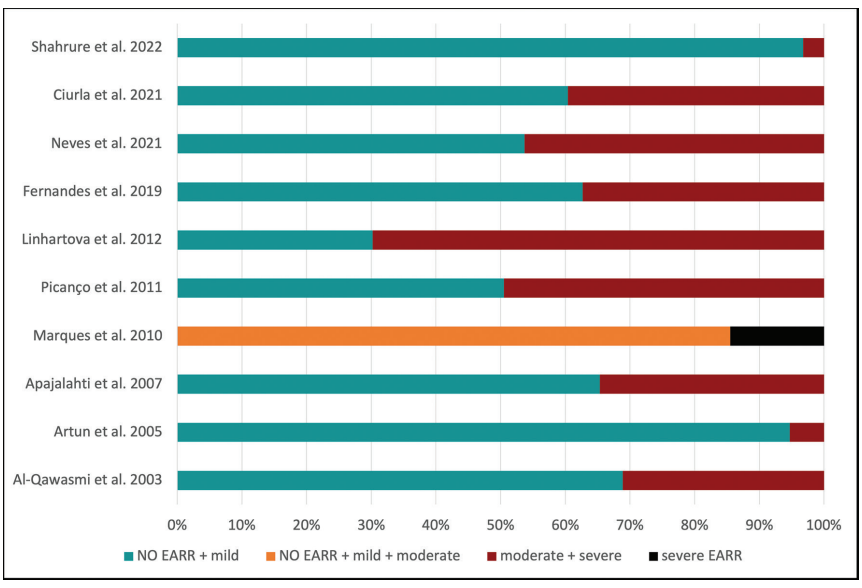

Supplementary File 4. EARR prevalence diagnosed using 2D methods divided into two or three categories.
EARR, external apical root resorption

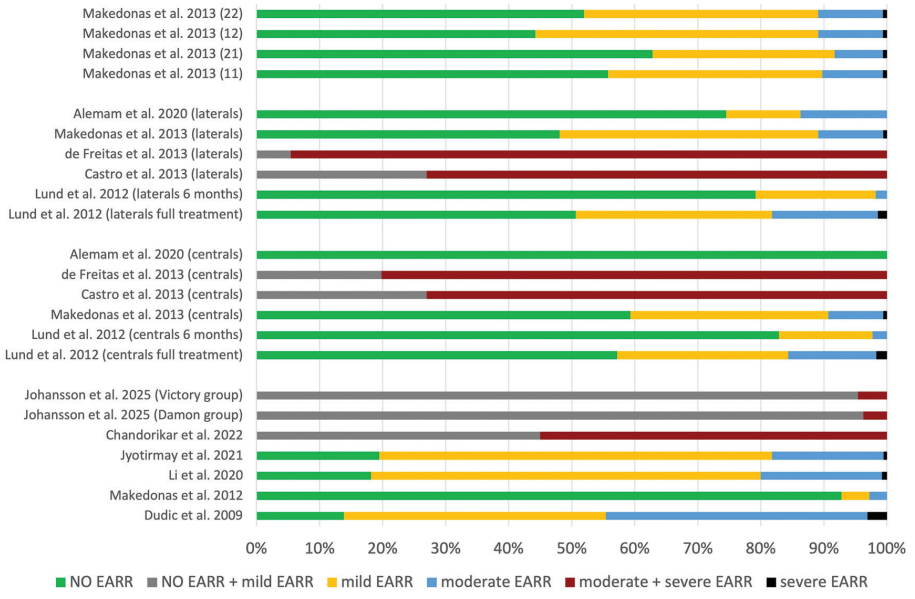

Supplementary File 5. EARR prevalence diagnosed using 3D methods in studies analysing fixed appliances.
EARR, external apical root resorption

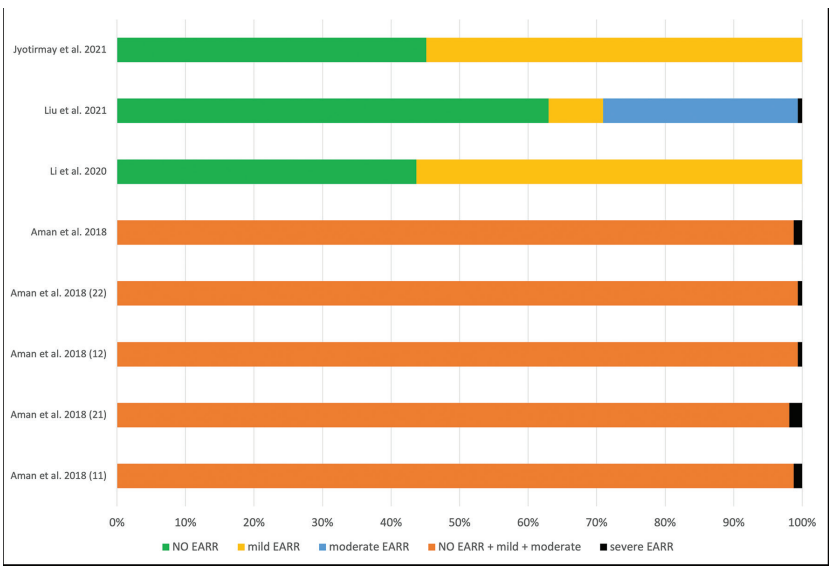

Supplementary File 6. EARR prevalence diagnosed using 3D methods in studies analysing clear aligners.
EARR, external apical root resorption