



ORIGINAL ARTICLE

# Combined Use of Retraction and Torque Arch with Mini-Screws: A Cephalometric Study

Mihri Amasyalı<sup>1</sup>, Fidan Alakuş Sabuncuoğlu<sup>2</sup>, Şeniz Karaçay<sup>3</sup>, Mehmet Doğru<sup>4</sup>, Handan Altuğ<sup>1</sup>

<sup>1</sup>Department of Orthodontics, Gülhane Training Hospital, Ankara, Turkey

<sup>2</sup>Department of Orthodontics, Sağlık Bilimleri University, Ankara, Turkey

<sup>3</sup>Department of Orthodontics, Sultan Abdülhamid Training Hospital, Istanbul, Turkey

<sup>4</sup>Department of Orthodontics, Dicle University School of Dentistry, Diyarbakır, Turkey

Cite this article as: Amasyalı M, Alakuş Sabuncuoğlu F, Karaçay Ş, Doğru M, Altuğ H. Combined Use of Retraction and Torque Arch with Mini-Screws: A Cephalometric Study. Turk J Orthod 2017; DOI: 10.5152/TurkJOrthod.2018.17031

## ABSTRACT

**Objective:** Our objective was to investigate and quantify the treatment of micro-implant-aided retraction and torque (R&T) arch on dentofacial structures.

**Methods:** Twelve patients (mean age 21.2 years) who required orthodontic camouflage treatment were included in the study. Following the canine distalization, mini-screws were placed between maxillary first molars and second premolars, and R&T arch was applied for the retraction of incisors. The vertical retraction arms of the arch were adjusted between the apex of the lateral incisor and the alveolar bone so that the retraction force passed through the center of resistance of four incisors and forced the incisors to bodily retraction. Closed coil-springs applying 150 gr of force were used to retract the incisors. The retraction period lasted for 217±34 days.

**Results:** SNA and NV-A decreased ( $p<0.05$ ), indicating alveolar bone remodeling around Point A. The reduction in the SNA caused a statistically significant decrease in the ANB ( $p<0.01$ ). SN/1, NA/1, NA-1, and overjet decreased significantly ( $p<0.01$ ), depending on the retrusion of the incisors. The distances from the apex and incisal point of the central incisor to the SV reference plane also decreased significantly ( $p<0.01$ ), revealing a nearly parallel movement of the incisors. Anchorage loss of the molars and decrease in nasolabial angle were not significant ( $p>0.05$ ).

**Conclusion:** A combined use of R&T arch with mini-screws is an effective method to retract the incisors without anchorage loss. The type of movement is nearly parallel.

**Keywords:** Mini screw, retraction and torque, arch

## INTRODUCTION

An increased procumbency of the upper lip and convex profile are seen due to overjet of upper incisors in patients with Class II Division I malocclusion, or Class I bimaxillary dentoalveolar protrusion. Orthodontic treatment of such patients aims to reduce teeth proclination and to improve the relation between the teeth and lips, and thus provide the patient with a more linear profile (1). The retraction of upper incisors plays an important role in the functions of the stomatognathic system, frontal and profile esthetic views of the face, and the stability of orthodontic therapy. However, the mechanics that would be performed to enhance the anchorage of posterior teeth should be accurately planned prior to the retraction of incisors (2, 3).

Anchorage control plays a key role in both structural and facial esthetics of patients. Maximum anchorage is required when 75% of the extraction cavity has to be covered by anterior teeth. Various techniques have been developed to provide maximum anchorage (4). Traditional methods, such as torque and tip-back bending, intermaxillary elastics, extraoral force, transpalatal arch, or Nance appliance can be used to enhance the orthodontic anchorage (5, 6). Skeletal anchorage screws are preferred when absolute anchorage is required. The use of mini-screws has become widespread within the last years because they can be placed (safe zone) during any phase of development, the force can be applied immediately, and there is no need for patient cooperation. Easy use

for both the patient and physician and low cost are other advantages of mini-screws (7, 8). These screws are temporary anchorage units and have smooth surfaces since they have not been designed for osseointegration. Therefore, they are not available for long-term functional and esthetic use, and they are removed when anchorage is not needed anymore. Today, the most frequently used temporary skeletal anchorage devices include micro-screws, mini-screws, mini-implants, palatal implants, and modified mini-plaques (9).

Bae et al. (10) suggested that micro-implants placed between the second premolar and the first molar could be used with a closed coil spring for the retraction of maxillary incisors. Kawakami et al. (11) placed a mini-screw between the first and second molars and enhanced the anchorage of posterior regions by attaching these implants to the molar bands. Upadhyay et al. (12) performed mass retraction of 6 anterior teeth by applying 150 gr force on micro-screws. Park et al. (13) also performed mass retraction by using micro-screws, and they reported approximately 4-months shorter treatment period with only 0.26 mm anchorage loss.

Retraction and torque (R&T) arch is a retraction wire developed by F. G. Sander and produced in two different compositions for the anterior and posterior segments (14). Two posterior segments are made of stainless steel wire, whereas anterior segment is made of super elastic wire. The anterior segment has been produced in three different diameters so that it could be used in two different bracket systems with .018 and .022 slots. However, the posterior segment has a diameter of .017x.022 only. The anterior segment has a torque of 30° or 45° (Table 1). Palatal root torque is given to the incisor region by attaching the anterior and posterior segments angularly to each other with a piece of crimping. There are vertical, stainless steel retraction arms soldered to the attachment point of anterior and posterior segments. During retraction of incisors, the force is applied to the teeth via closed coil-springs, which are attached to these vertical arms. Literature review revealed that R&T arch wire has not been widely used in the orthodontic practice. Various methods have been used to counteract torque loss in conjunction with retraction of maxillary anterior teeth. One of these is a biomechanic method in which the retraction force vector is optimized, such as R&T arch together with lever arms and mini-screws. The null hypothesis tested was that the use of R&T arch together with lever arms and mini-screws would be more beneficial than sliding mechanics for the treatment of patients requiring maximum anchorage.

## METHODS

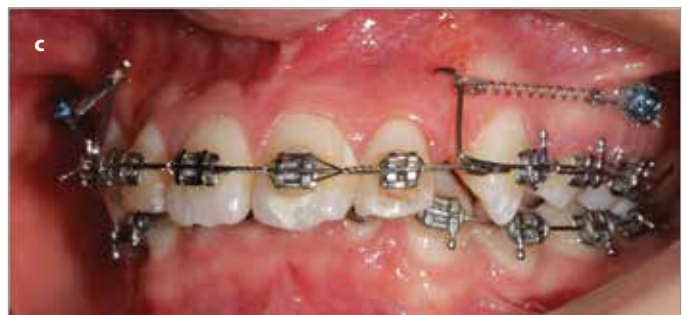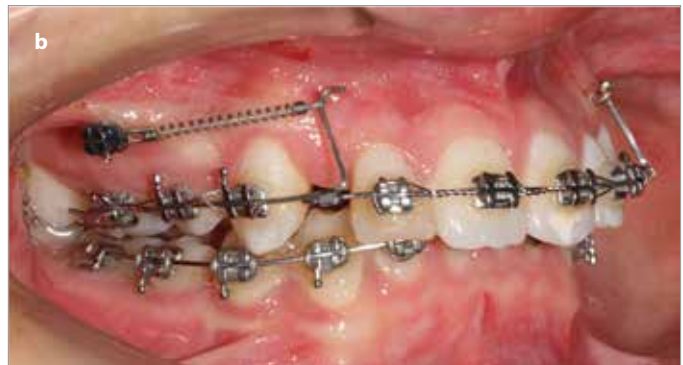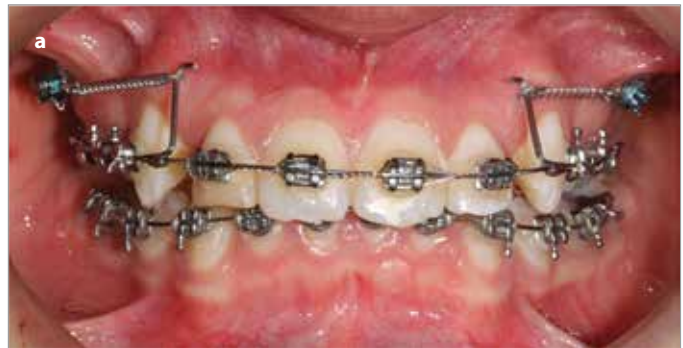This study was approved by the ethical committee on research of the Sağlık Bilimleri University in Ankara, Turkey.

The present study comprised 12 patients with the mean age of  $21.2 \pm 3.1$  years. The inclusion criteria were as follows:

- Eruption of all permanent teeth without congenital absence of any tooth
- Presence of Class II Division I malocclusion and obvious proclination of upper central incisors
- An overbite within the normal ranges

**Table 1.** Production of arch wire (R&T)

Technical	Dimensions		
	Front segment	Torque	Lateral Segment
0.18	0.016x.022	30	0.017x.022
0.18	0.016x.022	45	0.017x.022
0.22	0.017x.025	30	0.017x.022
0.22	0.017x.025	45	0.017x.022

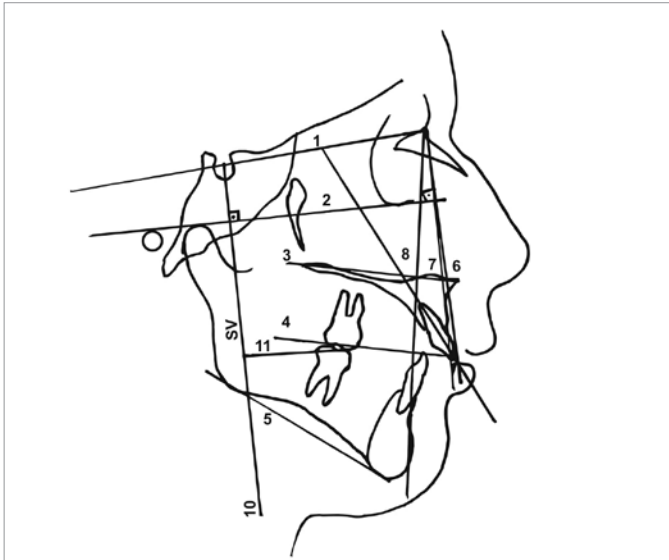


**Figure 1. a-c.** Clinical setup for retraction and torque arch with mini-screw

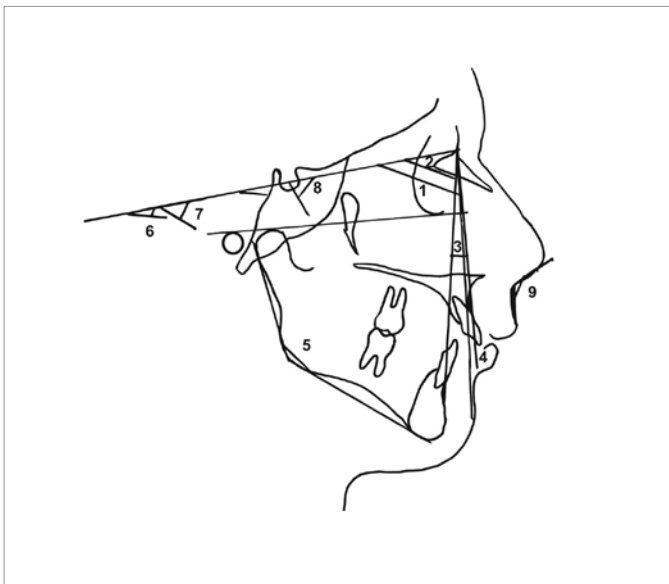
1. a. Intraoral frontal image
1. b. Intraoral left image
1. c. Intraoral right image

- Regular order of lower incisors or minimal irregularity not exceeding 2-3 mm
- Maximum anchorage cases that require camouflage treatment by eliminating excessive overjet with extraction of maxillary first premolars
- Completed active growth period
- No congenital disease or systemic problem

After the extraction of first premolars, Nance appliance and .018 slot Roth brackets were attached. Following the leveling phase,

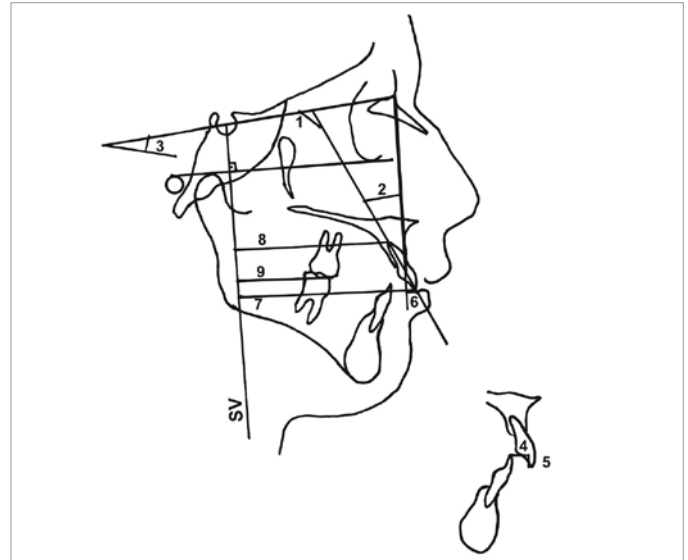


**Figure 2.** Cephalometric planes used in this study: 1) SN; 2) FH; 3) Palatal plane (PP); 4) Occlusal plane (OP); 5) Mandibular plane (MP); 6) N vertical (NV); 7) NA; 8) NB; 9) 1/NA; 10) Vertical reference plane perpendicular from S to FH (SV); 11) perpendicular distance from mesial cusp tip of maxillary first molar to SV



**Figure 3.** Skeletal and soft tissue measurements: 1) SNA; 2) SNB; 3) ANB; 4) NV-A; 5) Gonial angle; 6) SN/PP; 7) SN/MP; 8) Y-axis; 9) Nasolabial angle

0.16×0.16 stainless steel arch wire was applied, and lace-back was performed for canine distalization. Thereafter, a mini-screw (Miniscrews AbsoAnchor, Dentos, Daegu, Korea; diameter, 1.3 mm; length 8 mm) was placed between the first molar and the second premolar and R&T arch with an anterior segment of .016×.022, and a torque value of 45° was applied for the retraction of incisors. Closed coil-springs (Sentalloy, Tomy, Tokyo, Japan) applying 150 gr force were inserted between the mini-screws and the vertical loop of the R&T arch to retract the incisors (Figure 1a–c). The patients were followed up at 3-week intervals, and at the end of the incisor retraction period that lasted for 217±34 days, final settling of the occlusion was provided by intraoral elastics.



**Figure 4.** Dental measurements: 1) 1/SN; 2) 1/NA; 3) SN/OP; 4) Overjet; 5) Overbite; 6) 1-NA; 7) Vertical distance between the incisal point of the maxillary central incisor and SV (SV-U1i); 8) Vertical distance between the apical point of the maxillary central incisors and SV (SV-U1r); 9) Vertical distance between the mesial cusp tip of the maxillary first molar and SV (SV-U6t)

Lateral cephalometric radiographs were taken twice in all the patients: T1, before the retraction (after leveling for eliminated initial protrusion of the incisors), and T2, after closure of the extraction spaces. To evaluate the skeletal alterations SNA, SNB, ANB, Nv-A, Go, Y-axis, SN/PP, SN/MP were used. To evaluate the dental alterations SN/Occ, SN/1, NA/1, NA-1, overjet, overbite were measured. The nasolabial angle was used to determine the soft tissue. Despite these conventional analyses, a vertical reference plane (SV) from sella, perpendicular to Frankfort Horizontal plane, was reconstructed, and the vertical distances from the apex and incisal point of the maxillary central incisor were measured to determine the amount of horizontal movement of the maxillary incisor. Skeletal, dental, and soft-tissue measurements are illustrated in Figures 2-4.

### Statistical analysis

Cephalometric measurements were made on cephalograms taken before T1 and after T2 the retraction of incisors to assess dental, skeletal, and soft tissue changes. The measurements of 5 randomly selected patients were repeated to control the personal drawing error level. Nonparametric Wilcoxon signed rank test was used to compare the paired values of measurements. Probability of 0.05 was considered significant.

### RESULTS

None of the 36 mini-screws failed before the end of the retraction period. In all the patients, increased overjet was eliminated, and Class I canine and Class II molar relation were attained at the end of orthodontic treatment that lasted for 217±34 days. In the evaluation of skeletal parameters, it was determined that decreases in SNA and Nv-A were statistically significant ( $p < 0.05$ ), indicating alveolar bone remodeling around Point A. The reduction in the SNA caused a statistically significant decrease in ANB ( $p < 0.001$ ).

**Table 2.** Evaluation of parameters

	T1	T2	p
SV-A	74.6±5.6	66.4±8.3	0.002
SV-C	82.7±5.6	73.6±8.1	0.002
SV-CM	48.2±7.2	48.3±7.2	0.655
Overbite	3.8±1.4	3.8±1.1	0.957
Overjet	6.5±0.5	3.4±0.5	0.001
NA-1	6.4±0.9	4.1±1.1	0.002
NA/1	23.8±3.3	21.7±3.3	0.015
SN/1	103.8±3.4	100.0±2.5	0.002
SN/Occ	17.3±3.7	17.4±3.6	0.552

SV-A: distance from SV (from sella, perpendicular to Frankfort Horizontal Plane) to A; SV-C: distance from SV (from sella, perpendicular to Frankfort Horizontal Plane) to C; SV-CM: distance from SV (from sella, perpendicular to Frankfort Horizontal Plane) to CM; NA-1: distance from NA to line joining crown tip and apex of upper incisor; NA/1: angle between NA and line joining crown tip and apex of upper incisor; SN/1: angle between SN and line joining crown tip and apex of upper incisor; SN/Occ: angle between SN and occlusal plane

**Table 3.** Evaluation of parameters

	T1	T2	p
SNA	80.1±2.1	79.5±2.0	0.052
SNB	74.7±2.7	74.7±2.7	1.000
ANB	5.4±1.1	4.8±1.1	0.011
Nv-A	0.5±3.7	-0.5±3.8	0.048
Go	127.8±3.0	129.3±3.6	0.027
Y-axis	62.6±3.5	64.1±2.7	0.048
SN/PP	9.8±1.5	10.0±1.5	0.405
SN/MP	35.9±5.1	36.5±5.4	0.250
PP/MP	28.1±5.9	28.3±4.8	0.660
Nasiolab	103.5±2.7	102.4±1.9	0.263

SNA: angle between S-N and N-A; SNB: angle between S-N and N-B; ANB: angle between A-N and N-B; Nv-A: distance from NA to A; Go: angle between Ar, Go, and Gn points; Y-axis: angle between SN to SGn; SN/PP: angle between SN and palatal planes; SN/MP: angle between SN and mandibular planes; PP/MP: angle between ANS-PNS- and Go-Gn; Nasiolab: angle between the bottom of the nose (subnasale) and the top of the lip (labrale superius)

Evaluation of dental parameters revealed that SN/1, NA/1, NA-1, and overjet decreased significantly ( $p<0.01$ ), depending on the retrusion of incisors. The distances from the apex and incisal point of the central incisor to SV reference plane also decreased significantly ( $p<0.01$ ), revealing parallel movement of the incisors. The distance between the cusp tip of the first molar and SV reference plane increased, but this increase was not significant, meaning that the anchorage loss was negligible ( $p>0.05$ ). Remodeling around Point A and retrusion of the incisors caused a decrease in nasolabial angle, but this decrease was statistically insignificant ( $p>0.05$ ) (Tables 2 and 3).

## DISCUSSION

Angle Class II Division 1 malocclusion is the most frequent form of malocclusion according to the epidemiological surveys (15).

One of the treatment approaches to reduce the increased overjet in adult patients is camouflage treatment that consists of the extraction of maxillary first premolars to allow retraction of the anterior segment maintaining the disto-basal jaw relationship (16). Patients who required camouflage treatment were included in our study, and increased overjet was corrected with a combined use of R&T arch wire with mini-screw.

Ricketts et al. (17) defined that canines and four incisors exist on different planes in the space and defended that they should be retracted independently from each other because of this difference. Therefore, in our study, canine distalization was done prior to the retraction of incisors. An R&T arch with 45° palatal torque was preferred in our study. This torque prevents tipping of incisors and forces the teeth to parallel movement. To provide maximum anchorage, mini-screws were placed between the first molar and second premolar, and retraction force was applied on the incisors by using open coil-springs fixed on these screws. Samuels et al. (18) reported that 150 gr and 200 gr closed coil-springs produce more consistent space closure than an elastic module, and the researchers found no significant difference regarding the rates of space closure caused by 150 gr and 200 gr springs. In our study, open coil-spring applying 150 gr force was used.

When the distance from the apex of molars and mesial cusp tip to the SV reference plane was measured, no anchorage loss was observed in the posterior teeth. On the other hand, Dinçer et al. (19) found an anchorage loss with tipping movement of molar teeth during the retraction of upper incisors with both PG spring and open-coil spring systems, despite the use of transpalatal arch in the open-coil spring group. Upadhyay et al. (12) compared micro-screws and conventional anchorage methods during the retraction period of incisors and observed no anchorage loss in the molar region during the retraction with mini-screws. Park et al. (13) and Yao et al. (1) compared mini-screws and conventional methods during the retraction period of incisors and reported superiority of mini-screws over the conventional methods with regard to anchorage loss.

In our study, a statistically significant reduction was observed in SN/1, NA/1, and NA-1 parameters at the end of retraction period of 217±34 days. The height of the right and left vertical arms of the R&T arch was arranged to be in the middle of the root of lateral incisor so that the force passed through the center of resistance of maxillary four incisors. Thus, incisors were forced to bodily movement, which is more difficult and takes more time as compared to tipping movement. Evaluating the distance from the apex and incisive margin of central incisor to SV reference plane, it was detected that the apex and incisive margin moved 8.2 mm and 9.1 mm respectively in the posterior direction, and the movement was nearly parallel. On the other hand, Demir et al. (20), who evaluated the effects of camouflage treatment in patients with Class II Division I malocclusion, reported lingual tipping of upper incisors rather than bodily retraction, depending on the lack of third-order control. Sarıkaya et al. (21) found that maxillary incisors moved 4.5 mm in the lingual direction at the coronal level, 3 mm at the cervical level, and 1.5 mm at the apical level. The type of movement in that study was not pure

translation, but rather a controlled tipping. Upadhyay et al. (12) as well used mini-screws as an anchorage during the retraction of incisors and detected that maxillary anterior incisors were retracted primarily by controlled tipping and partly by translation.

The nasolabial angle is made up of both the soft tissue (pronasale) and the cartilaginous (columella) portions of the nose, which continues to grow forward, as well the soft tissue of the upper lip. In some studies, there were significant changes in the nasolabial angle resulting from tooth extraction (22, 23). However, this study concurs with the study of Janson et al. (24). Almeida et al. (25) displayed a statistically insignificant nasolabial angle change. The nasolabial angle did not respond uniformly to the retraction of the upper incisors in this study. This was probably due to the use of different reference planes or difference in soft tissue thickness. This indicates a high number of variables, including differences in soft tissue thickness and tension between individuals. This was probably due to the use of different reference planes or difference in soft tissue thickness.

In our study, retraction of the incisors caused a remodeling around the Point A. The SNA angle decreased at the end of the retraction period revealing that the A-point was located further posterior relative to the anterior cranial base after treatment. This decrease also caused a reduction in the ANB angle. These results concur with the study of Bravo (26) in which patients who had 4 premolar extractions were compared with those who never had a premolar extraction. The results of this study showed that the A-point was retruded by the retrusion of the maxillary incisors. Similar to our study, Vardimon et al. (27) stated that the movement of the root in the posterior direction caused a remodeling at the labial cortical bone.

In the present study, no statistically significant change was observed regarding palatal, occlusal, and mandibular plane angles. Stagers (28), who compared the treatment with and without a first premolar extraction, found statistically insignificant increase in the mandibular plane angle in both groups. Although the retraction of maxillary incisors and remodeling at Point A caused an increase in the nasolabial angle, this increase was not statistically significant in our study. This result is compatible with the results of Conley et al. (29) and Weyrich et al. (30). In the present study, overbite did not change significantly. Although the incisive margin was remarkably retracted, a significant vertical change was not observed. Whereas the results concerning overbite are consistent with the results of the PG retraction group, they are inconsistent in terms of the type of upper-incisor movement in the sagittal plane.

## CONCLUSION

The null hypothesis was accepted. The findings of our study are as follows:

1. A combined use of R&T arch wire with mini-screws is an effective method to retract the incisors without the anchorage loss.
2. When the vertical retraction arms of the R&T arch are adjusted between the apex of the lateral incisor and the deep-

est point of the alveolar bone, the retraction force passes through the center of resistance of four incisors and provides bodily retraction.

3. There are a few limitations to the present study as there is no control group and no different study methods. Further studies using different retraction methods with a control group are needed.

**Ethics Committee Approval:** Ethics committee approval was received for this study from the Ethics Committee of Sağlık Bilimleri University.

**Informed Consent:** Written informed consent was obtained from all the patients who participated in this study.

**Peer-review:** Externally peer-reviewed.

**Author Contributions:** Concept - M.A.; Design - Ş.K.; Literature Search - M.D.; Writing Manuscript - M.A.; Other - F.A.S.

**Conflict of Interest:** No conflict of interest was declared by the authors.

**Financial Disclosure:** The authors declared that this study has received no financial support

## REFERENCES

1. Yao CC, Lai EH, Chang JZ, Chen I, Chen YJ. Comparison of treatment outcomes between skeletal anchorage and extraoral anchorage in adults with maxillary dentoalveolar protrusion. *Am J Orthod Dentofacial Orthop* 2008; 134: 615-24. [\[CrossRef\]](#)
2. Tweed CH. *Clinical Orthodontics*. St Louis, Mo: Mosby; 1996.
3. Smith RJ, Burstone CJ. Mechanics of tooth movement. *Am J Orthod* 1984; 85: 294-307. [\[CrossRef\]](#)
4. Nanda R, Kuhlberg A. *Biomechanics in clinical orthodontics*. Philadelphia, PA: WB Saunders Company; 1996; p. 156-87.
5. Gianelly AA, Bednar J, Cociani S, Giancotti F, Maino G, Richter OP. *Bi-dimensional technique theory and practice*. Rapid City, SD: Fenwyn Press; 2000; p. 148-53.
6. Bishara SE. *Textbook of Orthodontics*. Philadelphia, PA: WB Saunders Company; 2001; p. 354-59.
7. De Clerck H, Geerinckx V, Siciliano S. The Zygoma Anchorage System. *J Clin Orthod* 2002; 36: 455-59.
8. Choi NC, Park YC, Lee HA, Lee KJ. Treatment of Class II protrusion with severe crowding using indirect miniscrew anchorage. *Angle Orthod* 2007; 77: 1109-118. [\[CrossRef\]](#)
9. Nanda R, Uribe FA. *Temporary anchorage devices in orthodontics*. St Louis, Mo: Elsevier Mosby; 2008; Chapter 1.
10. Bae SM, Park HS, Kyung HM, Kwon OW, Sung JH. Clinical application of micro-implant anchorage. *J Clin Orthod* 2002; 36: 298-302.
11. Kawakami M, Miyawaki S, Noguchi H, Kirita T. Screw-type implants used as anchorage for lingual orthodontic mechanics: a case of bimaxillary protrusion with second premolar extraction. *Angle Orthod* 2004; 74: 715-19.
12. Upadhyay M, Yadav S, Nagaraj K, Patil S. Treatment effects of mini-implants for en-masse retraction of anterior teeth in bialveolar dental protrusion patients: a randomized controlled trial. *Am J Orthod Dentofacial Orthop* 2008; 134: 18-29. [\[CrossRef\]](#)
13. Park HS, Yoon DY, Park CS, Jeoung SH. Treatment effects and anchorage potential of sliding mechanics with titanium screws compared with the Tweed-Merrifield technique. *Am J Orthod Dentofacial Orthop* 2008; 133: 593-600. [\[CrossRef\]](#)

14. Retraction and torque arch [http://www.forestadentcanada.com/pdfs/Wires%20arches%20arch%20wires%20\(collate\)/retration%20spring\\_en.pdf](http://www.forestadentcanada.com/pdfs/Wires%20arches%20arch%20wires%20(collate)/retration%20spring_en.pdf)
15. Bilgic F, Gelgor IE, and Celebi AA Malocclusion prevalence and orthodontic treatment need in central Anatolian adolescents compared to European and other nations' adolescents. *Dental Press J Orthod* 2015; 20: 75-81. [\[CrossRef\]](#)
16. Kinzinger G, Frye L, Diedrich P. Class II treatment in adults: comparing camouflage orthodontics, Dentofacial orthopedics and orthognathic surgery. *J Orofac Orthop* 2009; 70: 63-91. [\[CrossRef\]](#)
17. Ricketts RM, Bench RW, Gugino CF, Hilgers JJ, Schulhof RJ: Bioprogessive therapy, Book I, Denver, Rocky Mountain Orthodontics; USA, 1979.
18. Samuels RH, Rudge SJ, Mair LH. A clinical study of space closure with nickel-titanium closed coil springs and an elastic module *Am J Orthod Dentofacial Orthop* 1998; 114: 73-79. [\[CrossRef\]](#)
19. Dinçer M, Gülşen A, Türk T. The retraction of upper incisors with the PG retraction system. *Eur J Orthod* 2000; 22: 33-41. [\[CrossRef\]](#)
20. Demir A, Uysal T, Sari Z, Basciftci FA. Effects of camouflage treatment on dentofacial structures in Class II division 1 mandibular retrognathic patients *Eur J Orthod* 2005; 27: 524-31. [\[CrossRef\]](#)
21. Sarikaya S, Haydar B, Ciğer S, Ariyürek M. Changes in alveolar bone thickness due to retraction of anterior teeth. *Am J Orthod Dentofac Orthop* 2002; 122: 15-26. [\[CrossRef\]](#)
22. Booi JW, Goeke J, Bronkhorst EM, Katsaros C, Ruf S Class II treatment by extraction of maxillary first molars or Herbst appliance: dento-skeletal and soft tissue effects in comparison. *J Orofac Orthop* 2013; 74: 52-63 [\[CrossRef\]](#)
23. Luecke PE 3rd, Johnston LE Jr. The effect of maxillary first premolar extraction and incisor retraction on mandibular position: testing the central dogma of "functional orthodontics". *Am J Orthod Dentofacial Orthop* 1992; 101: 4-12. [\[CrossRef\]](#)
24. Janson G, Fuziy A, de Freitas MR, Castanha Henriques JF, de Almeida RR. Soft-tissue treatment changes in Class II Division 1 malocclusion with and without extraction of maxillary premolars. *Am J Orthod Dentofacial Orthop* 2007; 132: 729.e1-8. [\[CrossRef\]](#)
25. de Almeida-Pedrin RR, Henriques JF, de Almeida RR, de Almeida MR, McNamara JA Jr. Effects of the pendulum appliance, cervical headgear, and 2 premolar extractions followed by fixed appliances in patients with Class II malocclusion. *Am J Orthod Dentofacial Orthop* 2009; 136: 833-42. [\[CrossRef\]](#)
26. Bravo LA. Soft tissue facial profile changes after orthodontic treatment with four premolars extracted. *Angle Orthod* 1994; 64: 31-42.
27. Vardimon AD, Oren E, Ben-Bassat Y. Cortical bone remodeling/tooth movement ratio during maxillary incisor retraction with tip versus torque movements. *Am J Orthod Dentofac Orthop* 1998; 114: 520-529. [\[CrossRef\]](#)
28. Staggers JA, Germane N. Clinical considerations in the use of retraction mechanics. *J Clin Orthod* 1991; 25: 364-369.
29. Conley Scott R, Jernigan C. Soft tissue changes after upper premolar extraction in Class II camouflage therapy. *Angle Orthod* 2006; 76: 59-65.
30. Weyrich C, Lisson JA. The effect of premolar extractions on incisor position and soft tissue profile in patients with Class II, Division 1 Malocclusion. *J Orofac Orthop* 2009; 70: 128-138. [\[CrossRef\]](#)